




Contents lists available at ScienceDirect

Journal of Cranio-Maxillo-Facial Surgery

journal homepage: www.jcmfs.com

Simultaneous Le Fort I osteotomy and zygomatic implant placement

Francesco Grecchi ^a, Emma Grecchi ^b, Massimo Del Fabbro ^{a, b}, Funda Goker ^{b, *}^a IRCCS Orthopedic Institute Galeazzi, Via Riccardo Galeazzi, 4, 20161, Milano, Italy^b University of Milano, Department of Biomedical, Surgical and Dental Sciences, Milan, Italy

ARTICLE INFO

Article history:

Paper received 22 January 2021

Received in revised form

4 November 2021

Accepted 1 December 2021

Available online xxx

Keywords:

Zygomatic implant

Le fort I osteotomy

Orthognathic surgery

Atrophic maxilla

Dental implant

Oral rehabilitation

3D virtual surgical planning

Immediate loading

ABSTRACT

The aim of this retrospective study was to evaluate the outcomes of simultaneous LeFort I osteotomy and zygomatic/dental implant placement for oral rehabilitation of patients with extremely atrophic/dysmorphic edentulous maxilla.

Simultaneous LeFort I osteotomy and zygomatic/dental implant placement was performed with patient-specific anatomical models and surgical guides produced through three-dimensional virtual planning methods. All patients received their final prosthesis, with immediate loading, on the day after surgery. The primary outcome variables were the implant survival rate, and the incidence of intra/postoperative complications. In total, 15 zygomatic implants and 33 conventional dental implants were inserted in eight patients. The mean follow-up of the patients was 38.5 months. The implant survival rate was 93.3% for zygomatic implants and 100% for dental implants. No intra/postoperative complications were observed.

Simultaneous LeFort I osteotomy associated with zygomatic/dental implant surgery can be considered as a valuable treatment option for rehabilitation of patients with extremely atrophic edentulous maxilla and esthetic issues of the face.

© 2021 European Association for Cranio-Maxillo-Facial Surgery. Published by Elsevier Ltd. All rights reserved.

1. Introduction

The LeFort I osteotomy is one of the most commonly used orthognathic surgery procedures for the correction of malocclusion and maxillomandibular deformities (Buchanan et al., 2013; Matsuo et al., 2010). Le Fort I osteotomy, as a preimplant therapy, dates back to 1987 (Keller et al., 1987), while osteotomy with interpositional bone grafts and dental implants was described first by Bütow and Duvenage in 1993. Subsequently, Grecchi et al. (2009) tested Le Fort I osteotomy for maxillary advancement, grafts, and immediate loading with conventional dental implants. As a result, they reported a significantly shortened time of rehabilitation without adverse effects (Grecchi et al., 2009).

Over recent years, computer-aided design/computer-aided manufacturing (CAD/CAM) for maxillomandibular reconstruction has gained increasing popularity (Tarsitano et al., 2018; Aboul-Hosn Centenero and Hernández-Alfaro, 2012; Hirsch et al., 2009; Sharaf

et al., 2010; Mazzoni et al., 2013; Zheng et al., 2012). Currently, CAD/CAM-guided surgery with customized reconstructive plates is a rapidly developing technology, which has helped to ensure the safety and accuracy of these operations (Olszewski et al., 2010; Elnagar et al., 2020; Corneliussen et al., 2015; Stokbro et al., 2014; Lin et al., 2018; Grecchi et al., 2010; Busato et al., 2017; Tarsitano et al., 2016; Matsuo et al., 2010; Jeon, 2019). Various patient-specific surgical guides and devices have been designed and manufactured using 3D printing (Hirsch et al., 2009; Sharaf et al., 2010; Zheng et al., 2012; Mazzoni et al., 2013). These provide benefits such as patient satisfaction, and optimal functional and esthetic results (Bell, 2018; Elnagar et al., 2020; Stokbro et al., 2014; Lin et al., 2018).

Orthognathic surgery combined with conventional and/or zygomatic implant insertion has been reported by various authors in the literature, with or without CAD/CAM technology (Kim et al., 2018, 2019; Landes et al., 2013; Nocini et al., 2014; Kreissl et al., 2007). However, there is a lack of clinical studies in the literature reporting results of simultaneous orthognathic surgery and implant insertion utilizing CAD/CAM technology. Currently, there are conflicting reports on orthognathic surgery with immediate loading of zygomatic/dental implant insertions, and there remains a lack on

* Corresponding author.

E-mail addresses: dr.grecchi@tiscali.it (F. Grecchi), emma.grecchi@gmail.com (E. Grecchi), massimo.delfabbro@unimi.it (M. Del Fabbro), funda.goker@unimi.it (F. Goker).

decision making for optimum treatment modality and timing. The purpose of our study was to evaluate the outcomes of CAD/CAM-guided simultaneous Le Fort I osteotomy and zygomatic/conventional implant placement, without additional bone grafts, for rehabilitation of patients who present severe esthetic problems of the midface with extremely atrophic/dysmorphic edentulous upper jaws.

2. Case series

This retrospective case series study involved patients who were treated in the Department of Dentistry and Maxillofacial Surgery, IRCCS Orthopedic Institute Galeazzi, Italy, between November 2015 and November 2019. The study was approved by the IRB (institutional scientific review board) of Galeazzi Hospital, Milan, Italy (authorization number: Prot.Dsc 75/2019-L2057). The study protocol was in compliance with the principles laid down in the Declaration of Helsinki, and a signed informed consent form was obtained from all the patients.

2.1. Inclusion criteria

- Patients older than 18 years, with extremely atrophic/dysmorphic maxilla.
- Esthetic problems of the face, which could be identified as a lack of bone in both vertical and horizontal dimensions, representing an advanced loss of vertical dimension of the face, accompanied with an aged expression.
- Edentulous atrophic maxilla.
- Patients who were treated with simultaneous Le Fort I osteotomy and zygomatic/dental implant placement, without any bone grafts.
- Mobilization of the osteotomized edentulous maxilla in the three spatial dimensions that did not exceed 6 mm due to anatomical limits to displacement.

Exclusion criteria:

- Recent myocardial infarction, cerebrovascular problems, valvular prosthesis surgery, bleeding problems, or active treatment of malignancy, including head and neck radiotherapy, in the past 12 months.
- History of drug abuse, psychiatric illness, or intravenous bisphosphonate use within the previous 2 years.
- Immunosuppressive patients and patients with less than 6 mm residual bone in the premaxillary region.
- Patients who had received zygomatic implants without LeFort I surgery.

For this study, computer-aided design and computer-aided manufacturing (CAD/CAM) was used to perform surgery and prepare the upper denture, which was delivered the day after surgery. A computed tomography (CT) scan of each patient was obtained for presurgical planning using the Surgiplanner® tool (Biologitech, Italy). The Le Fort I osteotomy was performed with simultaneous dental/zygomatic implant insertions, using patient-specific surgical templates and guides produced with the aid of CAD/CAM technology.

A similar technique for Le Fort I osteotomy and conventional dental implant insertion was explained by the same team of researchers in a previous case series study (Grecchi et al., in 2009) and in a more recent case report (Busato et al., 2017). The protocol presented in this study is a modification, without any grafts, but with zygomatic implants inserted in addition to conventional dental implants.

2.2. Presurgical protocol

To obtain the desired esthetic and functional results, the Surgiplanner® tool was used to plan surgical and prosthetic phases virtually. Preoperative planning was performed by processing DICOM (Digital Imaging and Communications in Medicine) files of the patients' CT scans via the web-based Surgiplanner® tool service, with the support of a medical engineer. Le Fort I osteotomy of the atrophic maxilla, insertion of dental/zygomatic implants, and prosthetic rehabilitation were simulated on the 3D virtual models using standard triangle language (STL) files for 3D printing. After the final validation, patient-specific/custom-made maxillary bone surgical cutting guides, with STL models, implant drilling guide templates, and osteosynthesis plates (titanium grade 23 with 0.7 mm thickness) were manufactured by 3D printing within 15 working days.

The presurgical protocol included taking detailed health anamnesis from each patient, including clinical and radiological examinations. CAD/CAM was used to perform surgery and prepare the upper denture, which was delivered the day after surgery. A CT scan of the patient's skull was obtained for presurgical planning using the Surgiplanner® tool (Biologitech, Italy). The first step involved the construction of a 3D model of the facial skeleton of each patient, with maxilla and mandible, based on the CT scan. The Surgiplanner® tool was used to move the osteotomized maxilla segments in the three spatial planes, maintaining the correct relationship between condyle and skull base within the glenoid cavity. This also allowed the creation of a 3D model of the temporomandibular joint, and the reproduction of jaw movements in the three spatial planes. Control of the condylar movements allowed the reconstruction of functional occlusion in a fixed prosthesis. A 3D model of the patient's facial skeleton was then manufactured in a functional way, without the use of a facial arc transfer.

Next, the 3D model was mounted on a professional individual articulator created by the Surgiplanner® tool, and the cranial plane was adjusted parallel to a reference plane (such as the Frankfurt plane or intraorbital line of the patient). After mounting the maxillary model, the mandible was positioned by aligning the hinge axis with the axis of rotation of the articulator. The 3D model of the facial skeleton allowed examination of the position of the future prosthetic crowns in relation to the morpho-functional characteristics of each patient. A total upper denture with a correct occlusion and with teeth made of radio-opaque material was prepared and mounted on the 3D model of the facial skeleton to evaluate prosthetic rehabilitation for functioning and esthetics.

Subsequently, a second CBCT of the patient wearing the upper denture, and with metal landmarks on the skin, was taken from a lateral view. These landmarks allowed identification of the x-axis orbital plane, the central lower incisors, and the distal cusps of the two lower molars. A second cephalometric analysis was performed in order to evaluate the skeletal and functional relationships, the vertical dimension of the patient's face, and the occlusal plane, with the correct position and orientation of the upper and lower incisors. At this step, the dental elements of the denture were assessed for the size and form of future prosthetic crowns. The opinion of the patient was also taken into consideration, in order to satisfy the esthetic and functional expectations of each individual.

Next, the 3D models of the facial skeleton were remounted in the Surgiplanner® tool. Instrumental analysis was also performed to evaluate the occlusion. The volume and dimensions of the skull from the upper margin of the orbit to the entire mandible were then evaluated. The plane passing through the superior orbital margin was assigned parallel to the patient's orbital plane. The radio-opaque teeth portion of the upper denture was separated, adjusted, and connected to the palate of the 3D model via

appropriate connections. After the placement of the 3D models of the facial skeleton in Surgiplanner®, and the removal of the connections between the maxillary bone and teeth, analyses of the distance between the teeth and the residual bone, the quantity of bone loss, and the articular orientation relative to the axis–orbital plane were performed, in order to simulate the displacement of osteotomized maxilla segments. Instrumental analysis was also performed to evaluate the occlusion. Subsequently, the segment of the skeleton of the patient's face was repositioned in a pre-determined and controlled way, thus leading to a new skeletal structure. The upper jaw was detached and oriented into an appropriate position for a correct implant–supported prosthetic rehabilitation. The maxilla was then fixed with resin in the new position. The 3D model was scanned and built as a prototype for the orientation of custom-made plates, which allowed the surgeon to displace the osteotomized maxilla in the correct position during surgery. The 3D jaw was fixed using two plates or with two individualized commercially sold plates (TEKKA Srl., Italy).

The positions of the conventional and zygomatic implants were simulated in relation to the emergence of the prosthetic crowns, and the bone support template for the insertion of the implants was designed and produced. The virtual analysis allowed definition of the movements of bone segments, both qualitatively and quantitatively, in order to assess the new skeletal structure. At this point, changes in the position of the mandible in the three spatial directions was possible. The temporomandibular joints were additionally checked for reproducing the mandibular movements. The maxillary bone was then oriented with respect to the position of implant-supported prosthetic crowns. All the movements were measured in millimeters and/or degrees.

The soft tissues of the edentulous maxilla were reproduced, taking into account the thickness of the mucous membrane of the maxilla. The appropriateness of the prosthetic rehabilitation with respect to the objective of the planned surgery was then evaluated. In order to control the mobilization of the maxilla, a drilling template for the osteotomy was built. According to the surgeon's instructions, the maxillary osteotomy lines were anchored to the plates. The 3D model was then scanned and a prototype device prepared the drilling and osteotomy template, which would allow the surgeon to form holes and osteotomy lines exactly where planned. The osteotomy template was then used to manufacture the 3D model for surgery.

Next, the patient-specific surgical tools (templates for osteotomy and drilling osteosynthesis, and implant insertion), for controlling the mobilization and orientation of the skeletal segments during surgery, were manufactured. These tools offered the surgeon the possibility to orient the skeletal segments virtually in a suitable position for prosthetically guided implant placement. Custom-made conventional and zygomatic implant insertion guides were manufactured interactively by stimulating the position of each implant on each plane. The implant guide material used was acrylic with metal sleeves in five patients and 3D-printed titanium in three patients, while the zygomatic implant guide material was 3D-printed titanium for all patients.

The angulations, positions, and dimensions of the implants, and the inclinations of the multi-unit abutments, were then adjusted. The zygomatic implants were planned for an extra-sinus trajectory and were directed in a lateral, upward direction with angulations of around 45° and 52° from the vertical axis. The endpoints of the implants were calculated so as to be fixed into the zygomatic bone in a bicortical manner, for maximum anchorage. The final report was sent to the surgeon for approval, and the titanium surgical and implant positioning guides were produced (Fig. 1). The final step involved verification of the stereolithographic models mounted on Surgiplanner® by the surgeon.

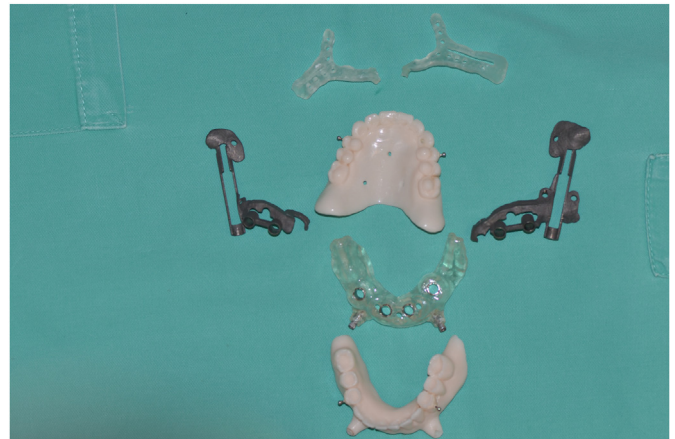

Fig. 1. Custom-made/patient-specific surgical templates and guides produced with the aid of CAD/CAM technology.

The zygomatic implants used in this study were Zygomatic Noris® (Noris Medical Ltd., Israel), and the dental implants were Noris® (Noris Medical Ltd., Israel) or Medentis® (Medical ICX GmbH, Germany).

2.3. Surgical procedures

Preoperative panoramic radiography and/or CBCT images of each patient were examined to evaluate the bone volume of the maxilla and to eliminate the risk of undiagnosed pathologies (Fig. 2a and b). The antibiotic regimen included augmentin 1 g tablets every 8 h for a total of 6 days or azithromycin 500 mg for 3 days in cases of allergy to penicillin. The surgeries were carried out by the same surgeon (FrG) under general anesthesia with endotracheal intubation.

Local anesthesia with vasoconstrictor (4% articaine with 1:100 000 adrenalin) was infiltrated labially and buccally from the pterygoid plate region, forward to the midline bilaterally. A horizontal incision was made 3–4 mm above the mucogingival junction with a #15 blade or electrocautery needle, extending from the maxillary 2 nd M to the contralateral 2 nd M (Fig. 3). The mucoperiosteal flap was elevated and the alveolar crest, anterior nasal spine, lateral maxillary wall, piriform opening, central and posterior part of the zygomatic complex, lateral wall of the maxillary sinus, infraorbital nerve emergence, and lower orbital rim were exposed. The osteotomy template was then used to perform the osteotomy (Figs. 4 and 5). At this point of the intervention, before the down fracture, the holes for positioning of the conventional implants were drilled using the custom-made osteotomy template for guidance.

The osteotomy template was then removed, and the down fracture of the maxilla was performed (special care was always taken with regard to pterygomaxillary disjunction, and the integrity of the nasal mucosa and the Schneiderian membrane) (Fig. 6). If down fracture is not performed properly, complete forward mobilization of the maxilla may not be achieved. In the worst-case scenario, a fracture in the atrophic maxilla may occur during the down-fracture procedure. After a successful down-fracture, the maxilla was oriented and fixed to its planned orthognathic position by means of custom-made plates and osteosynthesis screws, with further verification using a positioning acrylic guide that was fixed to the palate by an intermedial splint, with correct occlusion established according to the Surgiplanner® tool (Figs. 7 and 8).

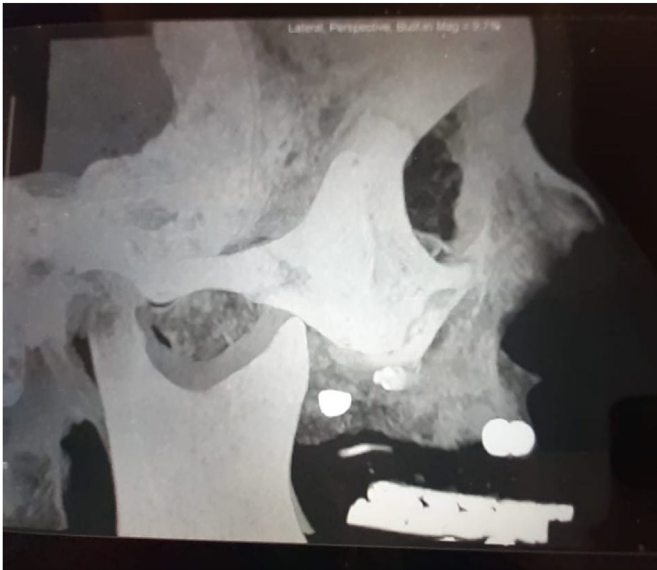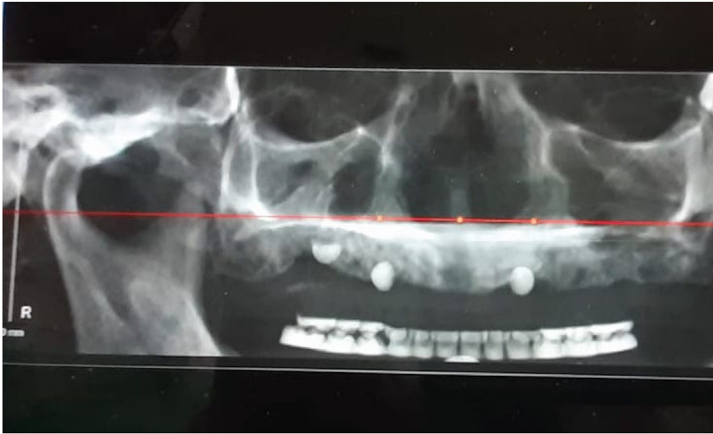


Fig. 2. Preoperative radiographs, showing the situation of the patient with edentulous maxillary bone and dysmorphia due to maxillary hypoplasia: (a) panoramic view; (b) lateral view.

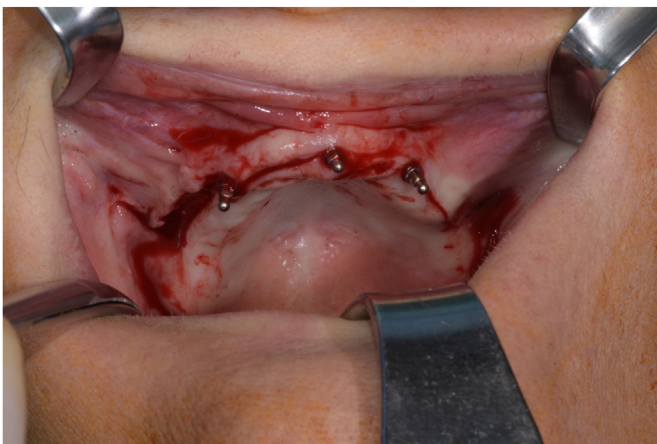


Fig. 3. Intraoral and intraoperative view of the patient, showing the surgical incision (*the mini-implants that can be seen in this photo were used only in this case. Before surgery, during the period of edentulism, these three mini-implants served temporarily to stabilize the mobile prosthesis. Additionally, during the surgery, they served as a guide and anchorage for the positioning acrylic guide. They were removed just before immediate loading).

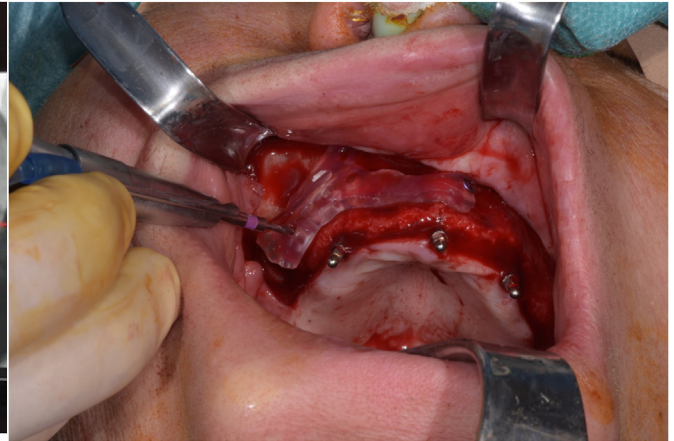


Fig. 4. Intraoperative view of the patient, showing the osteotomy template of the maxilla, which was fixed with titanium osteosynthesis screws.

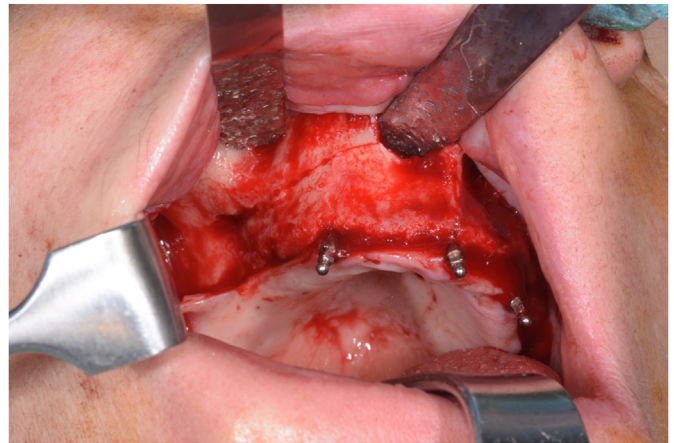

Fig. 5. Intraoperative view of the patient, showing the osteotomy.

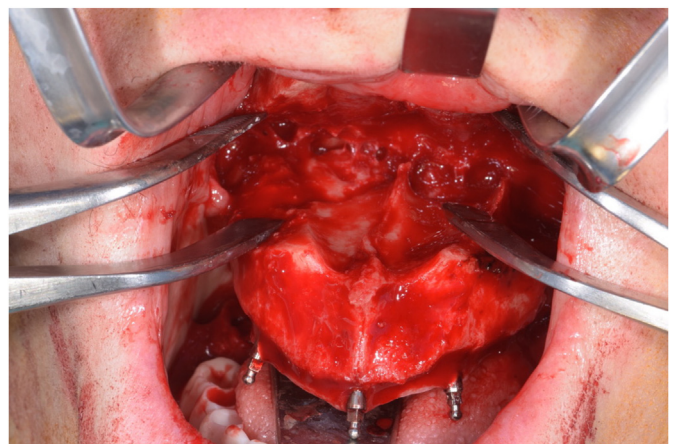


Fig. 6. Intraoperative view of the patient, showing down-fracture of the maxilla.

The surgery continued with dental and zygomatic implant placement according to the positioning grooves and holes on the patient-specific implant insertion guides (Fig. 9). The latter were produced with the use of CAD/CAM technology, comprising three guides in total for zygomatic and conventional implants: two

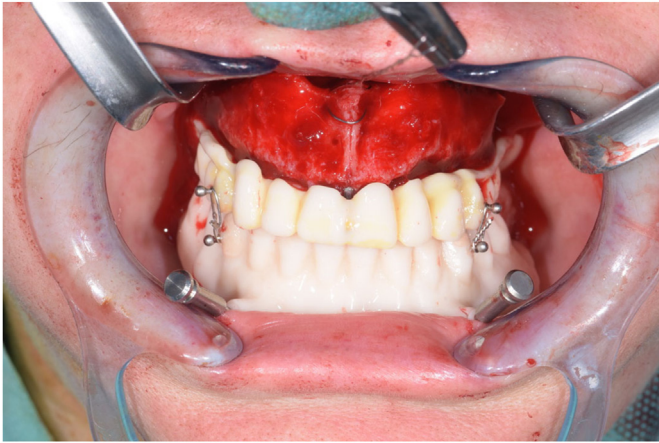


Fig. 7. Intraoperative view of the patient, showing the acrylic positioning guide that was fixed to the palatal bone by an intermedial splint, and verification of the orthognathic situation for the correct programmed movement of the maxilla.

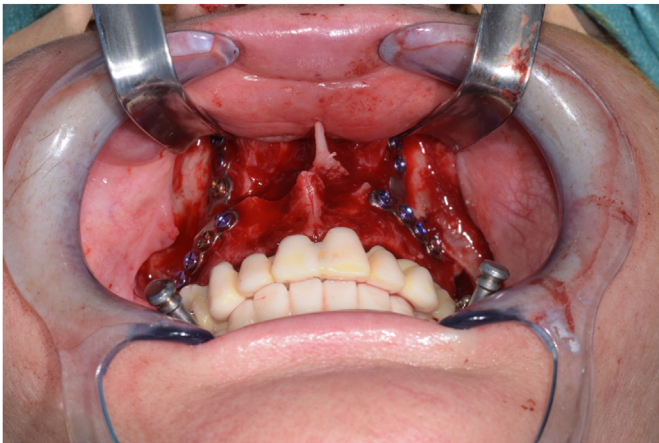


Fig. 8. Intraoperative view of the patient, showing fixation of the maxilla to its planned orthognathic position by means of custom-made plates and osteosynthesis screws.

titanium zygomatic implant guides (one for the left and one for the right side of the patient) and one conventional implant guide (acrylic with metal sleeves).

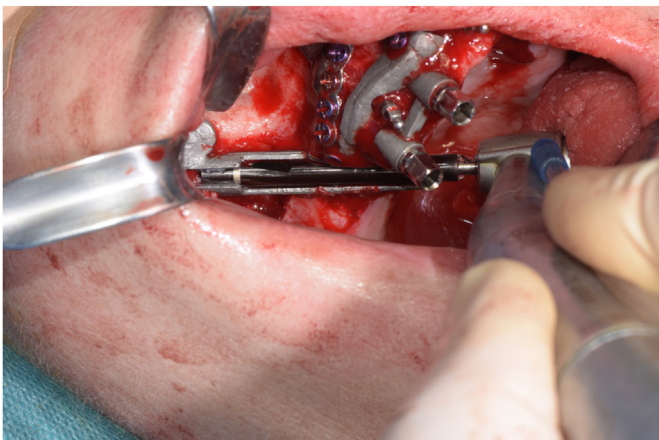


Fig. 9. Intraoperative view of the patient, showing the implant insertion guide.

Zygomatic implants were inserted following an 'extra-sinus protocol', which was previously explained in detail by the same team of authors (Goker et al., 2020a,b). However, in that earlier report (Goker et al., 2020a,b) none of the patients had received Le Fort I surgery, in contrast with the inclusion criteria for this study.

Subsequently, the conventional dental implants were placed under the control of patient-specific implant insertion guides (either one implant insertion guide, or two bilateral implant insertion guides) (Fig. 10).

The anterior dental implants were positioned with the apex projecting into the nasal cavity and into the osteotomy space created by the displacement of the maxilla. Zygomatic implants served as additional support for posterior osteosynthesis. The minimum torque for conventional implant insertions was 40 N cm, and that for zygomatic implants ≥ 60 N cm.

Pure collagen sponge (porous, absorbable, collagen scaffolding of bovine origin — Osteovit®; B Braun Surgical SA, Barcelona, Spain) was used for filling defects/residual spaces created by the Le Fort I osteotomy. Possible accidental lacerations of the sinus mucosa in the region of the alveolar crest were avoided using a Bichat fat pad and resorbable sutures. No autogenous bone or other bone graft material was used. The flaps were repositioned and sutured using continuous resorbable sutures (Vicryl, Ethicon FS-2; Johnson & Johnson, USA). Additionally, the suture involved a VY plasty at the upper lip for both esthetic and functional reasons.

Traditional protocols of orthognathic surgery were applied in this study. Attention was paid to the projection of the tip of the nose, the size and position of the conchae, the support of the nasolabial region, and the cheekbones. The external profile of the nose was treated in a particular way by remodeling the lateral bone edges of the piriformis opening and fixing the paranasal muscles to the nasal spine to avoid a possible supratype nasal deformity effect.

Postoperative panoramic X-rays were obtained from each patient following surgery (Fig. 11).

2.4. Prosthetic procedure and follow-up protocol

The final prosthesis was tested by the technician in the operating room, in order to verify the planned, perfect fit. In all cases presented in this study, the prostheses needed minor modifications and were adjusted within 24 h. The final definitive prostheses were delivered the day after surgery, and were loaded immediately. This immediate loading protocol served as an additive support for

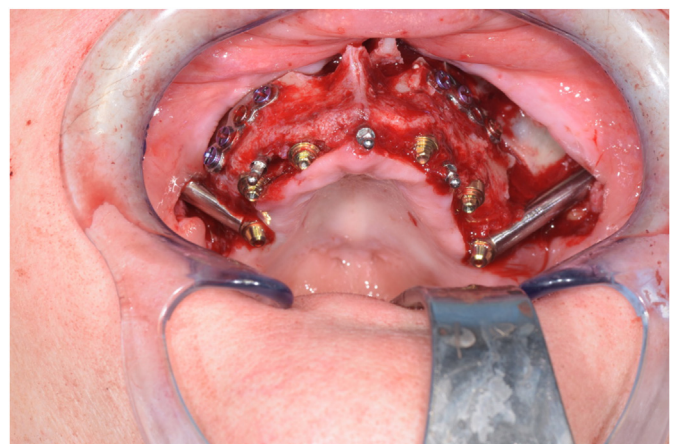


Fig. 10. Intraoperative view of the patient after insertion of four conventional and two zygomatic implants.

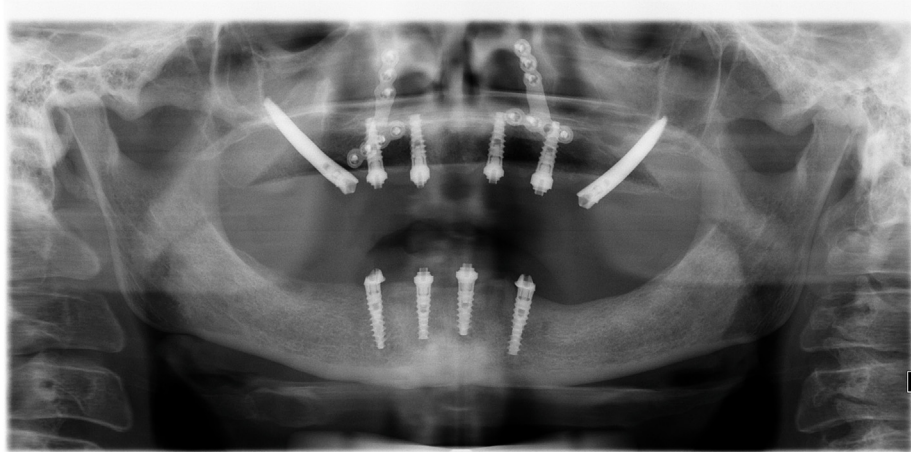


Fig. 11. Postoperative panoramic X-ray of the patient.

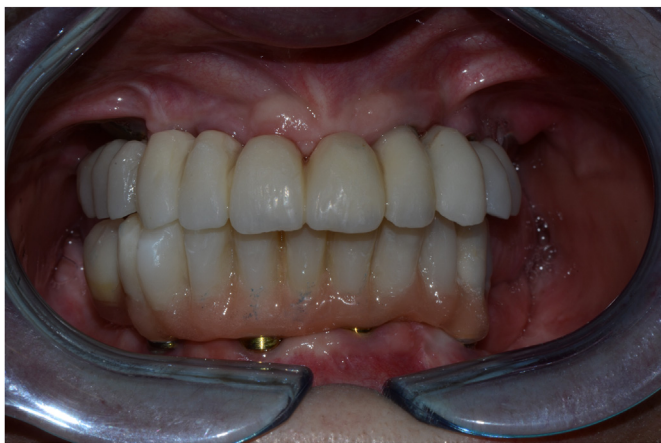

Fig. 12. Postoperative intraoral view of the patient after delivery of the final prosthesis, showing occlusion.

stabilization of the implants (Fig. 12), resulting in an enhanced quality of life for the patients. Fig. 13 shows the final prosthesis.

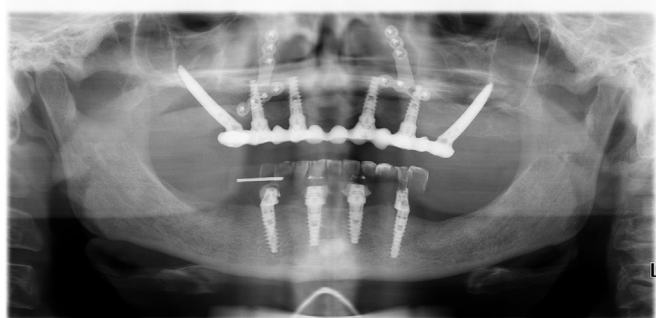


Fig. 13. Panoramic X-ray of the patient after delivery of the final prosthesis. Note that zygomatic implants in association with orthognathic surgery were chosen in this case due to the atrophic situation of the posterior sectors, in association with severe dysmorphism of the maxilla. Given the severe hypoplasia of the maxilla, it was necessary to support the lip with a large and bulky gingival flange in order to achieve a desirable and esthetic prosthetic rehabilitation. Alternative treatments would have provided esthetic and functional results, for example improved chewing, but not to the extent achieved here. The rehabilitation options were discussed with the patient, and consequently planned according to their request for a better esthetic result.

The patients were recalled for clinical follow-up after 10 days and 1 month, and then every 3 months for the first year, followed by twice a year. All patients were called for a maintenance program: every six months, professional scaling was carried out in order to check dentures and implants.

The occlusion was re-examined carefully on delivery of the final prostheses and at each follow-up. When required, additional panoramic X-rays were obtained at control appointments.

2.5. Outcome assessment

Implant success and survival rates were evaluated as the primary outcome, based on clinical and radiological criteria. Intra-operative and postoperative complications were evaluated as additional criteria for measuring success. Zygomatic and dental implants were considered successful according to the following criteria:

- Healthy peri-implant tissue condition, without any signs of peri-implantitis or peri-implant mucositis.
- No clinical mobility of the implants.
- No infection and no pain at the surgery site.
- No recession of the tissues around implants, with radiographic vertical bone loss less than 0.2 mm per annum (based on marginal bone loss evaluation of the mesial–distal aspects of the implants on orthopantomographic X-rays).
- Dental prosthesis functioning throughout the follow-up period, without major complications.
- No evidence of peri-implant radiolucency.
- No spontaneous implant failure.

With regard to prosthetic success, mechanical and/or technical complications that influenced the appropriate functioning of the prosthesis were additionally evaluated. These included pain, mobility, decementation of the prosthesis, bar fracture, and fractures or loss of bar-screw and/or abutment/screw fractures).

A single experienced evaluator assessed all the outcomes.

2.6. Statistical analysis

Descriptive statistics was carried out using mean values and standard deviations (SD) for quantitative variables that were normally distributed. Normality of distributions was assessed using the D'Agostino–Pearson omnibus test. The effects of the different

Table 1
Implant success rates according to patient characteristics, based on zygomatic implant number.

Patient	Characteristics	Failed ZI/total no. of ZI	Implant survival %	p-value
Gender	Male	0/2	100	0.87
	Female	1/13	92.3	
Reason for surgery	Severe atrophic maxilla	1/12	91.6	0.80
	Ectodermal dysplasia	0/3	100	
Smoking habits	Smokers	0/2	100	0.87
	Non-smokers	1/13	92.3	
Age	<60 years	1/13	92.3	0.87
	>60 years	0/2	100	
Antagonist dentition	Natural teeth/implants	1/8	87.5	0.53
	Fixed bridge	0/5	100	
	Toronto	0/2	100	
Final prosthesis type	Toronto	0/2	100	0.87
	Fixed-bridge prostheses with screws	1/13	92.3	
Number of ZI + I	1ZI + 5I	0/1	100	0.93
	2ZI + 4I	1/14	92.8	

variables (age, gender, smoking habits, zygomatic implant number, conventional implant number, final prosthesis type, antagonist dentition, and reason for surgery) on implant survival were evaluated using the Fisher's exact test, given the low incidence of failures in each group. Implants and patient numbers were evaluated separately as units of analysis. A *p*-value of 0.05 was considered as the significance threshold. Statistical analysis was performed using GraphPad Prism 5.03 (GraphPad Software, Inc., La Jolla, CA, USA).

In total, eight patients (seven female, one male), aged between 29 and 64 years (mean age = 57, SD = 12.28), and with severely atrophic maxilla, were included in this study. All the patients were treated with simultaneous Le Fort I osteotomy and dental/zygomatic implant placement. All patients had at least one zygomatic implant and four conventional dental implants inserted. The mean follow-up period for the patients was 38.5 (SD = 19.2) months (range 9–58 months).

Fifteen zygomatic implants and 32 standard dental implants were inserted. The overall survival rates were 100% and 93.3% for standard and zygomatic implants, respectively. There were no drop-outs during the total follow-up period. One zygomatic implant was lost after 11 months of function. In this case, the zygomatic implant was removed, and a new zygomatic implant was inserted. After 3 months, a definitive prosthesis was made, with loading of all the zygomatic implants. No additional intra/post-operative complications were observed.

All the patients had their final prosthesis delivered on the same day of surgery, with immediate loading.

Antagonist dentitions for the included patients comprised: one with natural dentition, two with natural teeth and dental implants, one with a fixed prosthesis over dental implants, three with fixed bridge restorations, and one with a resin Toronto bridge.

Final prostheses for the eight patients comprised: one resin Toronto bridge, six fixed bridge resin prostheses with screws (without any artificial gingival tissue preparations), and one fixed bridge zirconia prosthesis with screws (without any artificial gingival tissue preparations). All the final dentures had cast bars. There were no major or minor complications with the dental prostheses in any of the patients included in this study.

With regard to existing health problems, one patient had ectodermal dysplasia, seven had extremely severe maxillary atrophy, and one patient was a smoker. No other systemic health problems were recorded for any patient.

Implant survival rates and patient characteristics (age, gender, number of zygomatic and standard implants, type of final prosthesis, smoking habits, and antagonist dentition) are listed in [Tables 1 and 2](#) (on an implant basis and on a patient basis, respectively).

According to the results of this study, zygomatic/standard implant survival was not influenced by age, gender, smoking habits, implant number, final prosthesis type, or antagonist dentition. There were no statistically significant differences among the variables, and none of them was found to have any effect on implant failure. Aside from the lost implant, all implants evaluated fulfilled the success criteria, such that implant success was the same as survival.

All the patients had zygomatic implants inserted following the extra-sinus protocol. Details of the preoperative and postoperative ZAGA (zygoma anatomy-guided approach) classifications for each patient can be found in [Table 3](#). Changes in ZAGA classifications seen in some patients were due to the advancement of the maxilla. Further information on patient demographics and data regarding zygomatic and standard implant survival is provided in [Table 3](#).

3. Discussion

Le Fort I osteotomy with down-fracture and forward repositioning of the maxilla is a safe and successful method for correcting the anatomical intermaxillary relationship and to provide better esthetics ([Nocini et al., 2014](#); [Buchanan et al., 2013](#)). However, especially in patients with extremely atrophic edentulous maxilla, an additional bone grafting might be needed to obtain adequate bone volume for implant placement ([Nocini et al., 2014](#); [Buchanan et al., 2013](#)). Although this kind of treatment shows high success rates, various authors have proposed diverse protocols for decreasing morbidity and treatment times ([Pieri et al., 2012](#); [Grecchi et al., 2009](#); [Nocini et al., 2011](#)). As an alternative solution, the insertion of zygomatic implants has been reported to achieve excellent results ([Bedrossian, 2010](#); [Goker et al., 2020a,b](#); [Chrcanovic et al., 1949](#); [Davó et al., 2018](#); [Borgonovo et al., 2021](#); [Fernández-Ruiz et al., 2021](#)).

The clinical outcome of oral rehabilitation with immediately loaded zygomatic implants versus conventional implants placed in augmented bone has been evaluated in the literature by various authors ([Chow et al., 2006](#); [Bedrossian et al., 2006](#); [Davó et al., 2008](#); [Davó et al., 2018](#); [D'Agostino et al., 2021](#)). According to [Aparicio et al.](#), immediately loaded prostheses supported by zygomatic implants can help stabilize the implant arch and prevent stress on the healing bone by reducing lateral and rotational movements, thus allowing both rapid osseointegration and a good barrier formation, which can be effective in reducing complications ([Aparicio et al., 2000](#)). Currently, immediate loading is considered as a routine protocol for zygomatic implant surgery. In this study, the immediate loading concept was applied with promising results,

Table 2
Implant success rates according to patient characteristics, based on patient number.

Patient	Characteristics	Patients with ZI failure/total patient number	Implant survival %	p-value
Gender	Male	0/1	100	0.875
	Female	1/7	85.7	
Reason for surgery	Severe atrophic maxilla	1/7	83.3	0.875
	Ectodermal dysplasia	0/1	100	
Smoking habits	Smokers	0/1	100	0.875
	Non-smokers	1/7	85.7	
Age	<60 years	1/7	85.7	0.875
	>60 years	0/1	100	
Antagonist dentition	Natural teeth/implants	1/4	75	0.5
	Fixed bridge	0/3	100	
	Toronto	0/1	100	
Final prosthesis type	Toronto	0/1	100	0.875
	Fixed-bridge prostheses with screws	1/7	85.7	
Number of ZI + I	1ZI + 5I	0/1	100	0.875
	2ZI + 4I	1/7	85.7	

Table 3
Patient demographics and data regarding zygomatic and dental implant survival.

Age	Sex	Smoker	Reason for surgery (ZAGA preop)	ZAGA postop	Dental implant	ZI number	Length of ZIs	ZI locations	Survival (months)	Antagonist dentition	Prosthesis type	Comp.	Survival % DI (n/total)	Survival % ZI (n/total)
1 58	F	No	Atrophic maxilla (ZAGA 2)	2	4	2	37.5 42.5	26 16	29 11 (fail)	Natural teeth and implants with ceramic crowns	Fixed zirconia bridge with screws	No	100	50
2 36	M	No	Atrophic maxilla (ZAGA 3)	2	4	2	40 40	26 16	48	Natural teeth	Fixed resin composite bridge with screws	No	100	100
3 61	F	No	Atrophic maxilla (ZAGA 4)	4	4	2	37.5 32.5	26 16	56	Natural teeth and implants with ceramic crowns	Fixed resin composite bridge with screws	No	100	100
4 64	F	Yes	Atrophic maxilla (ZAGA 4)	4	4	2	37.5 40	26 16	23	Toronto (resin)	Fixed resin composite bridge with screws	No	100	100
5 29	F	No	Ectodermal dysplasia (ZAGA 3)	2	5	1	37.5	26	58	Fixed bridge	Toronto (resin)	No	100	100
6 56	F	No	Atrophic maxilla (ZAGA 3)	2	4	2	42.5 45	26 16	53	Implants with ceramic crowns	Fixed resin composite bridge with screws	No	100	100
7 57	F	No	Atrophic maxilla (ZAGA 3)	3	4	2	40 42.5	26 16	9	Fixed bridge	Fixed resin composite bridge with screws	No	100	100
8 54	F	No	Atrophic maxilla (ZAGA 3)	2	4	2	32.5 32.5	26 16	18	Fixed bridge	Fixed resin composite bridge with screws	No	100	100

ZI: zygomatic implants, DI: conventional dental implant, Comp: complication.

which was in accordance with authors/clinicians who support this protocol.

Orthognathic surgery with zygomatic and/or conventional dental implant insertions have been investigated by various authors in the literature (Sailer, 1989, 1991; Bütow and Duvenage, 1993; Kim et al., 2018, 2019; Landes et al., 2013; Nocini et al., 2014; Kreissl et al., 2007). Our Le Fort I osteotomy protocol was a graftless, one-step surgery with orthognathic aims, and was not performed simply for reconstructive purposes — its primary purpose was the restoration of functional and stable occlusion. However, it was equally important to achieve good peri-oral soft tissue recovery in the 'smiling area', which is usually compromised in extreme alveolar ridge atrophy conditions. Furthermore, corrections of the alveolar ridges in the three spatial planes enabled better use of the endosseous implants.

Titanium implants with an increase in angulation of abutments (such as 15° and 25°) produce higher stresses compared with axial abutments (Guguloth et al., 2019). Implant survival can be improved by lowering the stress on the surrounding bone (Manea

et al., 2019). Due to biomechanical principles, and under perfect conditions, six dental implants with axis angulations of 5° can be inserted (Manea et al., 2019). Before the use of zygomatic implants, this therapy involved the insertion of additional implants in the grafted lateral sites during a second surgical step. In our study, the inclusion criteria of at least 6 mm of residual alveolar bone in the premaxilla was applied in order to carry out immediate loading with dental implants. The purpose was to achieve not only a good esthetic result in the middle third of the face, but also with regard to smiling and the intramucosal path of the teeth.

The possibility to perform a simultaneous Le Fort I osteotomy and zygomatic/conventional implant placement without bone grafts has been tested in clinical trials. The time interval between dental implant insertion and orthognathic surgery was one of the main concerns in these studies (Kim et al., 2018, 2019; Landes et al., 2013; Nocini et al., 2014). Clinical reports in the literature suggest that orthognathic surgery can impair the osseointegration of dental implants (Kim et al., 2018, 2019). The authors hypothesized that this was the result of the regional acceleratory phenomenon (RAP),

which is also seen after orthognathic surgery, and can have an unfavorable effect on dental implant osseointegration (Kim et al., 2018, 2019). RAP is a tissue reaction to a noxious stimulus that increases the healing capacities of the affected tissues (Verna, 2016). Consequently, microenvironmental changes in hard tissue induced by major surgery on the jaws can have negative effects on the integrity of biomaterial osseointegration. However, there is no consensus on the specific pathophysiological mechanism of RAP and its impacts on biomaterials (Kim et al., 2018, 2019).

Simultaneous Le Fort I osteotomy and dental/zygomatic implant placement without any additional bone grafts and with delayed prosthetic rehabilitation has been tested in a clinical computer-guided implant study, with promising results (Nocini et al., 2014). In our study, CAD/CAM-guided simultaneous Le Fort I osteotomy and zygomatic/dental implants with immediate loading was tested in selected cases, including patients with extremely atrophic edentulous maxilla and/or ectodermal dysplasia. CAD/CAM technology has several advantages over conventional methods. Extremely precise analysis of anatomical features, such as shape, size, and position of the maxilla, in relation to functional and esthetic aspects of the planned prosthesis was carried out before all interventions, and was discussed with the patient in terms of possible solutions.

Le Fort I osteotomy segments were determined in a controlled way, in order to obtain a new intermaxillary relation and skeletal structure. The final results of the maxillofacial surgery were simulated on 3D models before the surgery. Surgical templates for the osteotomy and repositioning were manufactured before the surgery, which helped to control the mobilization and orientation of skeletal segments during surgery. Additionally, careful evaluation of the positioning of the standard/zygomatic implants, and of prosthetic rehabilitation in relation to the maxillofacial surgical intervention, was performed in the presurgical phase.

The fundamental aspects of this Le Fort I osteotomy and dental implant insertion technique have been explained in previous articles by the same team of authors (Grecchi et al., 2009; Busato et al., 2017). A similar technique was explained previously in a case report involving the Surgiplanner® tool with Le Fort I osteotomy and standard dental implant insertion (without any additional zygomatic implants) (Busato et al., 2017). The novel aspects of the present protocol included the graftless modification, plus the combination of zygomatic and standard implants.

A further benefit of this approach was that the insertion of the zygomatic implants protected the anterior conventional implants from overloading. As a result, the occlusal system was more stable and had higher survival rates when compared with previous techniques, which included an additional waiting period for the lateral grafts to heal for loading. However, this one-step oral rehabilitation protocol should be used selectively. In order to preserve a minimum premaxillary bone residue for stabilizing the immediately loaded conventional implants, the mobilization of the osteotomized edentulous maxilla in the three spatial dimensions must not exceed 6 mm, due to the anatomical limits on displacement.

Landes et al. tested velopharyngoplasty and bilateral zygomatic implant insertions in a staged approach (Landes et al., 2013). In their study, subapical mandibular alveolar osteotomy was performed to reposition the alveolar process and teeth. Nocini et al. presented a case report on simultaneous Lefort I osteotomy and zygomatic implant placement, with delayed prosthetic rehabilitation (Nocini et al., 2014). In 2009, Grecchi et al. reported a one-step oral rehabilitation of the severely resorbed maxilla by means of conventional implant insertion, Le Fort I osteotomy for maxillary advancement, grafting, and immediate loading (Grecchi et al., 2009). In brief, when comparing our results with those in the

current literature relating to orthognathic surgery with zygomatic implant insertion, very few case reports were evident. Our sample size in assessing this graftless alternative, with immediately loaded zygomatic implants, albeit limited, was found to be higher than those in previous studies.

In this study, the initial esthetic problems of the patients were solved by performing the described surgery. The movement of the maxillary bone, together with the procedures involving the upper lip, improved the esthetics for all oral tissues. A digital smile design enabled a predictable esthetic result. The digital surgical protocol also enabled very precise reproduction of the planned surgery. The surgical simulation followed the established concepts relating to facial proportions that are used in conventional orthognathic surgery. In parallel with the virtual plan, stereolithographic models and occlusal simulations were produced to verify the precision of the bone-cutting templates and of the custom-made synthesis.

4. Conclusion

According to the results, the protocol presented in this study for oral rehabilitation, involving one-step simultaneous Le Fort I osteotomy and zygomatic/dental implant insertion with immediate loading, can be considered a valuable option for esthetic and functional rehabilitation of patients with extremely atrophic edentulous maxilla. The CAD/CAM guides increased the procedure's accuracy and safety. The retrospective design and the small sample size (eight patients), which is of limited relevance, can be considered as the main limitations of this study.

Funding statement

This research did not receive any specific grant from funding agencies in the public, commercial, or not-for-profit sectors.

Author contributions

FG, EG, MDF, and FrG conceived and designed the analysis. Databases were searched and data collected by FG, EG, MDF, and FrG. Maxillofacial surgical interventions and zygomatic implant insertions were performed by FrG. All the authors contributed to the analysis and interpretation of data. FG drafted and wrote the manuscript, with input from all authors. MDF, FG, EG, FrG assessed the manuscript critically for intellectual content. The integrity of the study was appropriately investigated and resolved by all authors. All authors contributed equally to, and approved, the final version of the manuscript.

Declarations of competing interest

None.

Acknowledgements

The authors would like to thank Dr Zingari for his helpful advice on temporary mini-implant placement for stabilization of the mobile prosthesis in one of the patients of the study group.

References

- Aboul-Hosn Centenero, S., Hernández-Alfaro, F., 2012. 3D planning in orthognathic surgery: CAD/CAM surgical splints and prediction of the soft and hard tissues results — our experience in 16 cases. *J. Cranio-Maxillo-Fac. Surg.* 40, 162–168. <https://doi.org/10.1016/j.jcms.2011.03.014>. Epub 2011 Mar 31. PMID: 21458285.
- Aparicio, C., Manresa, C., Francisco, K., Claros, P., Alandez, J., Gonzalez-Martin, O., Albrektsson, T., 2000. Zygomatic implants: indications, techniques and outcomes, and the Zygomatic Success Code, 2014 *Periodontology* 66, 41–58.

- Bedrossian, E., Rangert, B., Stumpel, L., Indresano, T., 2006. Immediate function with the zygomatic implant: a graftless solution for the patient with mild to advanced atrophy of the maxilla. *Int. J. Oral Maxillofac. Implants* 21, 937–942.
- Bedrossian, E., 2010. Rehabilitation of the edentulous maxilla with the zygoma concept: a 7-year prospective study. *Int. J. Oral Maxillofac. Implants* 25, 1213–1221.
- Bell, R.B., 2018. A history of orthognathic surgery in North America. *J. Oral Maxillofac. Surg.* 76, 2466–2481. <https://doi.org/10.1016/j.joms.2018.09.006>. PMID: 30502870.
- Borgonovo, A., Grandi, T., Vassallo, S., Signorini, L., 2021. Extrasinus zygomatic implants for the immediate rehabilitation of the atrophic maxilla: 1-year post-loading results from a multicenter prospective cohort study. *J. Oral Maxillofac. Surg.* 79, 356–365. <https://doi.org/10.1016/j.joms.2020.10.003>.
- Buchanan, E.P., Hyman, C.H., osteotomy, LeFort I., 2013. *Semin. Plast. Surg.* 27, 149–154.
- Busato, A., Vismara, V., Grecchi, F., Grecchi, E., Lauritano, D., 2017. Surgiplanner: a new method for one step oral rehabilitation of severe atrophic maxilla. PMID: 29285336; PMCID: PMC5735382 *Oral Implantol (Rome)* 10, 325–334. <https://doi.org/10.11138/orl/2017.10.3.325>.
- Bütow, K.W., Duvenage, J.G., 1993. Implant-orthognathic reconstructive surgery. A preliminary report. PMID: 8113424 *J. Cranio-Maxillo-Fac. Surg.* 21, 326–334. [https://doi.org/10.1016/s1010-5182\(05\)80491-3](https://doi.org/10.1016/s1010-5182(05)80491-3). discussion 335.
- Chow, J., Hui, E., Lee, P.K., Li, W., 2006. Zygomatic implants — protocol for immediate occlusal loading: a preliminary report. *J. Oral Maxillofac. Surg.* 64, 804–811.
- Chrcanovic, B.R., Albrektsson, T., Wennerberg, A., 2016. Survival and complications of zygomatic implants: an updated systematic review, 1949–1964 *J. Oral Maxillofac. Surg.* 74. <https://doi.org/10.1016/j.joms.2016.06.166>. Epub 2016 Jun 18. PMID: 27422530.
- Cornelius, C.P., Smolka, W., Giessler, G.A., Wilde, F., Probst, F.A., 2015. Patient-specific reconstruction plates are the missing link in computer-assisted mandibular reconstruction: a showcase for technical description. *J. Cranio-Maxillo-Fac. Surg.* 43, 624–629. <https://doi.org/10.1016/j.jcms.2015.02.016>. Epub 2015 Mar 2. PMID: 25934440.
- D'Agostino, A., Lombardo, G., Favero, V., Signoriello, A., Bressan, A., Lonardi, F., Nocini, R., Trevisiol, L., 2021. Complications related to zygomatic implants placement: a retrospective evaluation with 5 years follow-up. *J. Cranio-Maxillo-Fac. Surg.* 49, 620–627. <https://doi.org/10.1016/j.jcms.2021.01.020>. Epub 2021 Feb 5. PMID: 33581959.
- Davó, R., Malevez, C., López-Orellana, C., Pastor-Beviá, F., Rojas, J., 2008. Sinus reactions to immediately loaded zygoma implants: a clinical and radiological study. *Eur. J. Oral Implant.* 1, 53–60. PMID: 20467644.
- Davó, R., Felice, P., Pistilli, R., Barausse, C., Marti-Pages, C., Ferrer-Fuertes, A., Ippolito, D.R., Esposito, M., 2018. Immediately loaded zygomatic implants vs conventional dental implants in augmented atrophic maxillae: 1-year post-loading results from a multicentre randomised controlled trial. *Eur. J. Oral Implant.* 11, 145–161. PMID: 29806663.
- Elmagor, M.H., Aronovich, S., Kusnoto, B., 2020. Digital workflow for combined orthodontics and orthognathic surgery. *Oral Maxillofac. Surg. Clin.* 32, 1–14. <https://doi.org/10.1016/j.joms.2019.08.004>. Epub 2019 Nov 4. PMID: 31699582.
- Fernández-Ruiz, J.A., Sánchez-Siles, M., Guerrero-Sánchez, Y., Pato-Mourelo, J., Camacho-Alonso, F., 2021. Evaluation of quality of life and satisfaction in patients with fixed prostheses on zygomatic implants compared with the all-on-four concept: a prospective randomized clinical study. *Int. J. Environ. Res. Publ. Health* 18, 3426. <https://doi.org/10.3390/ijerph18073426>. Published 2021 Mar 25.
- Goker, F., Grecchi, E., Del Fabbro, M., Grecchi, F., 2020a. Clinical outcome of 302 zygomatic implants in 110 patients with a follow-up between 6 months and 7 years. *Clin. Implant Dent. Relat. Res.* 22, 415–423. <https://doi.org/10.1111/cid.12909>. Epub 2020 Apr 14. PMID: 32291961.
- Goker, F., Grecchi, E., Mancini, E.G., Del Fabbro, M., Grecchi, F., 2020b. Zygomatic implant survival in 9 ectodermal dysplasia patients with 3.5- to 7-year follow-up. *Oral Dis.* 24. <https://doi.org/10.1111/odi.13505>. Epub ahead of print. PMID: 32583493.
- Grecchi, F., Zollino, I., Parafioriti, A., Mineo, G., Pricolo, A., Carinci, F., 2009. One-step oral rehabilitation by means of implants' insertion, Le Fort I, grafts, and immediate loading. *J. Craniofac. Surg.* 20, 2205–2210. <https://doi.org/10.1097/SCS.0b013e3181bf8487>. PMID: 19884833.
- Grecchi, F., Mancini, G., Parafioriti, A., Mineo, G., Zollino, I., Pricolo, A., Carinci, F., 2010. Ectodermal dysplasia treated with one-step surgical rehabilitation: a case report. *Singapore Dent. J.* 31, 9–14. [https://doi.org/10.1016/S0377-5291\(12\)70003-2](https://doi.org/10.1016/S0377-5291(12)70003-2). Epub 2012 Jan 25. PMID: 23739251.
- Guguloth, H., Duggineni, C.R., Chitturi, R.K., Sujesh, M., Ravvali, T., Amiti, R.R., 2019. Correlation between abutment angulation and off-axial stresses on biomechanical behavior of titanium and zirconium implants in the anterior maxilla: a three-dimensional finite element analysis study. *J. Indian Prosthodont. Soc.* 19, 353–361. https://doi.org/10.4103/jips.jips_268_19. Epub 2019 Oct 10. PMID: 31649445; PMCID: PMC6803790.
- Hirsch, D.L., Garfein, E.S., Christensen, A.M., Weimer, K.A., Saddeh, P.B., Levine, J.P., 2009. Use of computer-aided design and computer-aided manufacturing to produce orthognathically ideal surgical outcomes: a paradigm shift in head and neck reconstruction. *J. Oral Maxillofac. Surg.* 67, 2115–2122.
- Jeon, J.H., 2019. Digital technology in orthognathic surgery: virtual surgical planning and digital transfer. *J. Korean Assoc Oral Maxillofac Surg* 45, 231–232. <https://doi.org/10.5125/jkaoms.2019.45.5.231>. Epub 2019 Oct 30. PMID: 31728329; PMCID: PMC6838355.
- Keller, E.E., Van Roekel, N.B., Desjardins, R.P., Tolman, D.E., 1987. Prosthetic-surgical reconstruction of the severely resorbed maxilla with iliac bone grafting and tissue-integrated prostheses. *Int. J. Oral Maxillofac. Implants* 2 (155–165). PMID: 3325418.
- Kim, J.W., Lee, H., Lim, H.K., Kim, J.W., Byun, S.H., Choi, Y.J., Lee, U.L., 2018. Orthognathic surgery deteriorates the osseointegration of dental implants: a propensity-matched multicenter cohort study. *J. Oral Rehabil.* 45, 967–973. <https://doi.org/10.1111/joor.12705>. Epub 2018 Sep 27. PMID: 30125391.
- Kim, J.W., Kim, H.Y., Kim, S.Y., Kim, S.J., 2019. Impaired osseointegration of dental implants associated with orthognathic surgery: possible regional acceleratory phenomenon. *Clin. Implant Dent. Relat. Res.* 21, 531–537. <https://doi.org/10.1111/cid.12745>. Epub 2019 Mar 18. PMID: 30884115.
- Kreissl, M.E., Heydecke, G., Metzger, M.C., Schoen, R., 2007. Zygoma implant-supported prosthetic rehabilitation after partial maxillectomy using surgical navigation: a clinical report. *J. Prosthet. Dent* 97, 121–128. <https://doi.org/10.1016/j.prosdent.2007.01.009>. PMID: 17394908.
- Landes, C., Zahn, T., Uhse, A., Lauer, H.C., Sader, R., 2013. Orofacial rehabilitation in maxillary aplasia: a patient evincing a premaxilla only, receiving zygomatic implants, orthognathic surgery, and double crown-supported prosthesis. *J. Craniofac. Surg.* 24, 296–300. <https://doi.org/10.1097/SCS.0b013e31828f2baa>. PMID: 23714998.
- Lin, H.H., Lonic, D., Lo, L.J., 2018. 3D printing in orthognathic surgery — a literature review. *J. Formos. Med. Assoc.* 117, 547–558. <https://doi.org/10.1016/j.jfma.2018.01.008>. Epub 2018 Feb 3. PMID: 29398097.
- Matsuo, A., Kono, M., Toyoda, J., Nakai, T., Tsuzuki, M., Chiba, H., 2010. Navigation surgery for Le Fort I osteotomy in a fibrous dysplasia patient. *Odontology* 98, 181–184. <https://doi.org/10.1007/s10266-010-0124-5>.
- Mazzoni, S., Marchetti, C., Sgarzani, R., Cipriani, R., Scotti, R., Ciocca, L., 2013. Prosthetically guided maxillofacial surgery: evaluation of the accuracy of a surgical guide and custom-made bone plate in oncology patients after mandibular reconstruction. *Plast. Reconstr. Surg.* 131, 1376–1385.
- Manea, A., Bran, S., Dinu, C., Rotaru, H., Barbur, I., Crisan, B., Armencea, G., Onisor, F., Lazar, M., Ostas, D., Bacut, M., Vacaras, S., Mitre, I., Crisan, L., Muresan, O., Roman, R., Bacut, G., 2019. Principles of biomechanics in oral implantology. *Med Pharm Rep* 92, 14–19. <https://doi.org/10.15386/mpr-1512>. Epub 2019 Dec 15. PMID: 31989104; PMCID: PMC6978931.
- Nocini, P.F., Bertossi, D., Albanese, M., D'Agostino, A., Chilosi, M., Procacci, P., 2011. Severe maxillary atrophy treatment with Le Fort I, allografts, and implant-supported prosthetic rehabilitation. *J. Craniofac. Surg.* 22, 2247–2254. <https://doi.org/10.1097/SCS.0b013e3182327817>. PMID: 22075829.
- Nocini, P.F., D'Agostino, A., Chiarini, L., Trevisiol, L., Procacci, P., 2014. Simultaneous Le Fort I osteotomy and zygomatic implants placement with delayed prosthetic rehabilitation. *J. Craniofac. Surg.* 25, 1021–1024. <https://doi.org/10.1097/SCS.0000000000000742>. PMID: 24705239.
- Olaszewski, R., Taney, O., Cosnard, G., Zech, F., Reyhler, H., 2010. Reproducibility of osseous landmarks used for computer tomography based three-dimensional cephalometric analyses. *J. Cranio-Maxillo-Fac. Surg.* 38, 214–221.
- Pieri, F., Lizio, G., Bianchi, A., Corinaldesi, G., et al., 2012. Immediate loading of dental implants placed in severely resorbed edentulous maxillae reconstructed with Le Fort I osteotomy and interpositional bone grafting. *J. Periodontol.* 83, 963–972.
- Sailer, H.F., 1989. A new method of inserting endosseous implants in totally atrophic maxillae. PMID: 2808708 *J. Cranio-Maxillo-Fac. Surg.* 17, 299–305. [https://doi.org/10.1016/s1010-5182\(89\)80057-5](https://doi.org/10.1016/s1010-5182(89)80057-5).
- Sailer, H.F., 1991. Neue Methoden zur oralen Rehabilitation. Die Kombination präprothetisch-chirurgischer Operationen mit enossalen Schraubenimplantaten [New methods of oral rehabilitation. Combination preprosthetic surgical operations with endosseous screw implants]. *Swiss Dent.* 12 (23–24), 26–27, 29 passim, 1991. German. PMID: 1819160.
- Sharaf, B., Levine, J.P., Hirsch, D.L., Bastidas, J.A., Schiff, B.A., Garfein, E.S., 2010. Importance of computer-aided design and manufacturing technology in the multidisciplinary approach to head and neck reconstruction. *J. Craniofac. Surg.* 21, 1277–1280.
- Stokbro, K., Aagaard, E., Torkov, P., Bell, R.B., Thygesen, T., 2014. Virtual planning in orthognathic surgery. *Int. J. Oral Maxillofac. Surg.* 43, 957–965. <https://doi.org/10.1016/j.ijom.2014.03.011>. Epub 2014 Apr 16. PMID: 24746388.
- Tarsitano, A., Ciocca, L., Scotti, R., Marchetti, C., 2016. Morphological results of customized microvascular mandibular reconstruction: a comparative study. *J. Cranio-Maxillo-Fac. Surg.* 44, 697–702.
- Tarsitano, A., Battaglia, S., Ricotta, F., Bortolani, B., Cercenelli, L., Marcelli, E., Cipriani, R., Marchetti, C., 2018. Accuracy of CAD/CAM mandibular reconstruction: a three-dimensional, fully virtual outcome evaluation method. *J. Cranio-Maxillo-Fac. Surg.* 46, 1121–1125.
- Verna, C., 2016. Regional acceleratory phenomenon. *Front Oral Biol* 18, 28–35. <https://doi.org/10.1159/000351897>. Epub 2015 Nov 24. PMID: 26599115.
- Zheng, G.S., Su, Y.X., Liao, G.Q., Chen, Z.F., Wang, L., Jiao, P.F., Liu, H.C., Zhong, Y.Q., Zhang, T.H., Liang, Y.J., 2012. Mandible reconstruction assisted by preoperative virtual surgical simulation. *Oral Surg Oral Med Oral Pathol Oral Radiol* 113, 604–611. <https://doi.org/10.1016/j.ortripleo.2011.05.016>. Epub 2011 Aug 19. PMID: 22676986.